

Expanding the Benefits of Implant Therapy: Implant-Retained Removable Partial Dentures

ROBERT C. VOGEL, DDS

ABSTRACT: *The multitude of benefits patients derive from implant-based therapy has been well documented for more than 20 years. Implant-based modalities have expanded the options for replacing teeth and returning function in both partial and fully edentulous situations. This article is not intended to review the predictability of fixed implant-supported restorations or the overwhelming health, psychological, and functional benefits derived from removable overdenture therapy. This article will present the clinical and social advantages of an alternative treatment option—implant-retained removable partial dentures—that allows more patients to benefit from implant-based care.*

The patient benefits derived from implant-based therapy through the predictability of fixed implant-supported restorations, as well as the health, psychological, and functional benefits of overdenture therapy are well documented.¹⁻³ There has been significantly less attention to the outstanding clinical and social advantages of alternative options that allow more patients to benefit from implant-based care.

Implant-retained removable partial dentures (RPDs) have made treatment options available to patients who previously may not have been able to benefit from implant dentistry because of

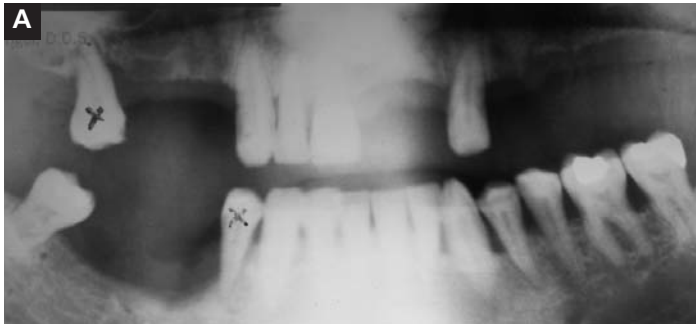

FIGURE 1A Initial presentation radiograph of a 53-year-old man before removal of periodontally compromised maxillary molar and implant placement.

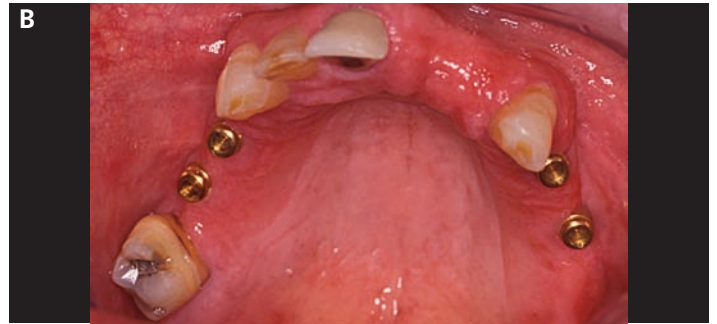

FIGURE 1B Partially edentulous maxilla after placement of four implants in areas of adequate bone volume and subsequent placement of Locator implant attachments.

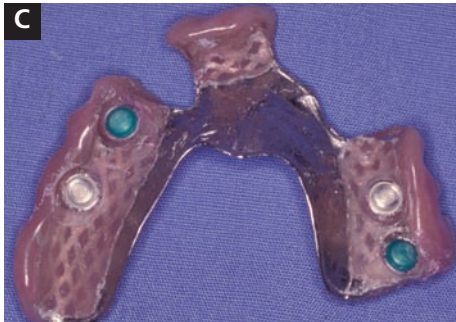

FIGURE 1C Tissue surface of clasplless implant-retained RPD with Locator housings and retentive inserts in place.

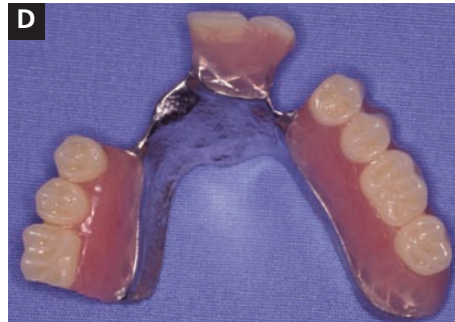


FIGURE 1D Implant-retained, tissue-supported final prosthesis.

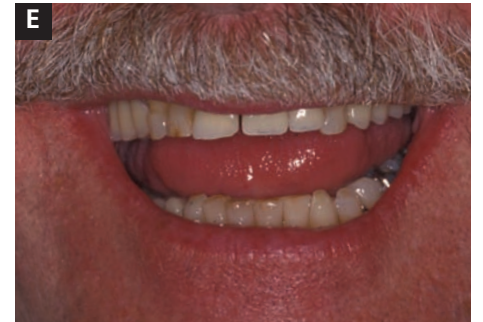

FIGURE 1E Delivery of appliance exceeded patient's desire for improved esthetics and ideal retention with elimination of clasps and movement as well as traumatic forces to remaining dentition.

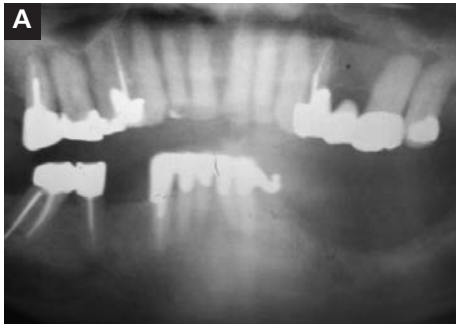


FIGURE 2A Initial presentation radiograph of 68-year-old man before loss of mandibular anterior bridge.

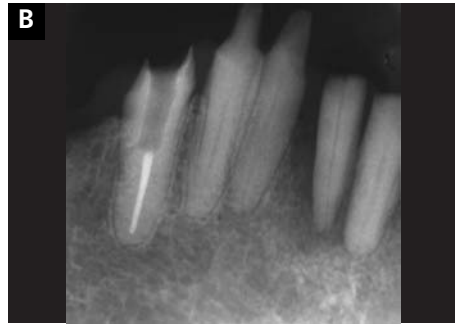


FIGURE 2B Mandibular anterior teeth following fracture and loss of bridge.

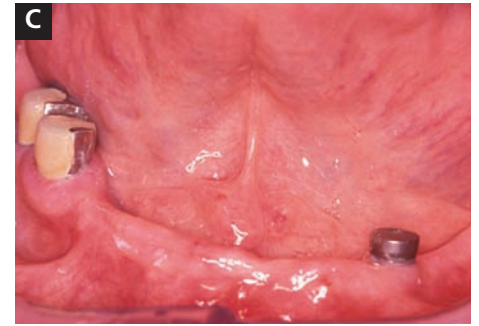


FIGURE 2C Long-span unilateral edentulous mandibular ridge after placement of one implant to eliminate chronic lifting of the saddle with associated food impaction and mucosal soreness.

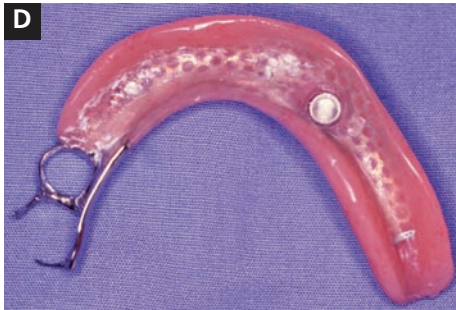

FIGURE 2D Tissue surface of tooth- and implant-retained appliance with housing and retentive component cured into base.

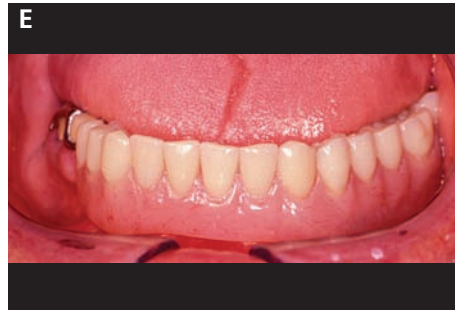

FIGURE 2E Delivery of prosthesis with verification of borders and tissue contact.

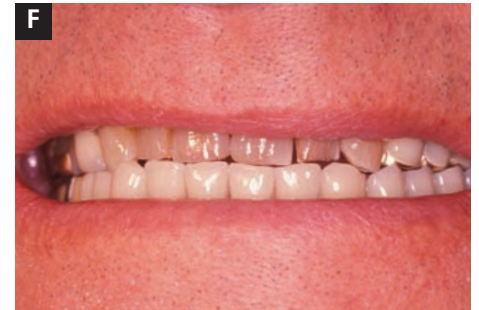

FIGURE 2F Final prosthesis in full occlusion and function with elimination of trauma to edentulous ridge and remaining teeth as well as ideal retention.

limitations in health, anatomy, finances, or social issues. This conservative treatment modality provides options for additional treatment in the future and accommodates changes in the remaining natural dentition.¹⁻³

Limitations to conventional fixed prosthesis are often a result of advanced ridge resorption, with concurrent loss of facial esthetics caused by lack of facial support of the lips and soft tissues of the face, as well as inadequate ridge form that precludes ideal implant placement. Other limiting factors to be considered in fixed implant-supported restorations include lack of hygiene access, multiple surgical procedures, and cost.

Limitations of conventional, nonimplant-supported RPD therapy⁴ include a lack of stability, minimal retention, periodontally compromised abutment teeth, and unesthetic clasps.⁵ These limitations frequently are accompanied by discomfort (of the underlying edentulous ridge), accelerated tooth loss, and traumatic forces, as well as patient reluctance to use the appliance routinely. Further, if a critical abutment tooth is lost, these appliances can be rendered useless.

While there has been minimal literature on this treatment option, a recent literature review⁶ indicated that the use of implants in conjunction with remaining natural teeth in the form of an implant-retained RPD provides patients with exceptional service and benefits not attainable with more conventional treatment options. Mijiritsky and colleagues⁷ found that patients receiving this treatment had only minor prosthetic complications, great satisfaction,

and improved chewing efficiency. The researchers determined that the treatment modality is viable and cost-effective. Other studies have confirmed improved esthetics,^{8,9} fewer patient visits,^{3,10} and the ability to avoid additional surgical procedures.

The placement of dental implants in an edentulous space not only provides the biologic benefit of reducing bone resorption,¹¹ but in the case of an implant-retained RPD, also provides distinct biomechanical advantage⁷ in reducing the effect of the reciprocal arm of a conventional RPD and improving the fulcrum line position, as well as offering superior retention and elimination of unesthetic clasps in the esthetic zone. The ability to have a flange on such a prosthesis also allows for replacement of facial esthetics and extraoral soft-tissue support lost from advanced ridge resorption. An implant-retained RPD also allows for the addition of prosthetic teeth with minimal modification to the prosthesis should a natural tooth be lost, as well as the ability to perform additional surgical procedures while maintaining the use of the prosthesis as a transitional appliance.

In this author's experience of placing more than 70 implant-retained RPDs, this modality has become a rewarding treatment option. For the patients, it has provided outstanding comfort and satisfaction. For the clinician, it has offered prosthetic simplicity and the ability to perform maintenance and modification over the long term. This modality also has provided the ability to transition patients into fixed implant-supported restorations through placement of additional implants with and without augmentation

procedures or to transition to a conventional implant overdenture after the loss of the remaining natural teeth. Further, these benefits are realized in a conservative and cost-effective manner.

CLINICAL CASES

The following clinical cases explore the rationale, design, and benefit of this treatment option. An important note of consideration in Cases 2 and 4 is that of the combined use of natural teeth and implants in one arch. As teeth are considered resilient because of the presence of a periodontal ligament, and osseointegrated implants are considered rigid because of direct contact with bone, the author recommends using a “resilient” implant attachment (Locator® implant attachment systems, Zest Anchors, Inc, Escondido, CA) to provide the level of resilience needed for an implant-retained, tissue-supported appliance³ and to allow for normal movement of the teeth.

Case 1

A 53-year-old man presented with an RPD that was esthetically unacceptable because the clasp was visible on the anterior teeth. Periodontally compromised abutment teeth created a lack of denture retention (Figure 1A). Treatment options were presented, including bilateral posterior augmentation with seven implants to provide a fixed restoration, which was not financially feasible for the patient at that time. Strategic placement of four implants in areas of adequate existing bone (Figure 1B) allowed for the fabrication of a clasplless partial denture (Figure 1C and Figure 1D) with ideal esthetics and

retention (Figure 1E). This option offered the ability to transition to a full-arch fixed restoration with grafting and additional implants or to a conventional maxillary overdenture if the remaining natural teeth were lost. Added benefits realized from this treatment were decreased mobility of the natural teeth through elimination of traumatic forces and retention of proprioception. This option also was more economically feasible for the patient.

Case 2

A 68-year-old man presented with a long-span unilateral edentulous mandible (Figure 2A and Figure 2B). The patient was unable to tolerate his existing RPD because of lifting of the saddle, which allowed food to enter, and chronic mucosal soreness of the edentulous ridge from food entrapment and rotational movement of the appliance. The patient had a desire to maintain his existing teeth as long as practical. The placement of one implant (Figure 2C and Figure 2D) provided ideal retention to eliminate lifting of the saddle and restricted the rotational movement to result in elimination of chronic mucosal sore spots as well as removal of traumatic forces from the remaining teeth (Figure 2E and Figure 2F). This conservative procedure allows for placement of additional implants, should they become necessary.

Case 3

A 62-year-old patient presented with a need for posterior occlusion. The six anterior teeth were periodontally stable but compromised by decay and abfraction in the gingival third (Figure 3A). A lack of posterior bone through resorption and sinus expansion precluded placement of implants distal to the first bicuspid region without significant augmentation. Health concerns were a consideration, limiting the number and extent of surgical procedures. Additionally, structural compromise of the natural teeth created a high risk of fracture if conventional clasping or full-coverage restorations were used. Bilateral placement of single implants (Figure 3B and Figure 3C) provided uncompromised retention and esthetics (Figure 3D) with the ability to transition to posterior fixed implant-supported bridges in the future if additional implants were placed. This conservative treatment option did not rely on compromised teeth for retention or require preparation of the teeth for full-coverage splinting, as would be required with a precision-attachment partial denture. The treatment also required only minimally invasive surgery and was cost-effective.

Case 4

A 70-year-old woman presented having recently lost her remaining mandibular right cuspid and first bicuspid (Figure 4A and Figure 4B). Placement of two implants

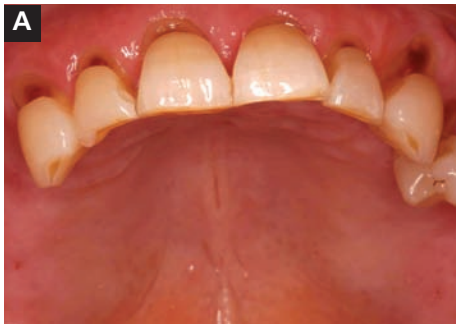

FIGURE 3A Partially edentulous maxilla with compromised remaining dentition and minimal posterior alveolar bone.

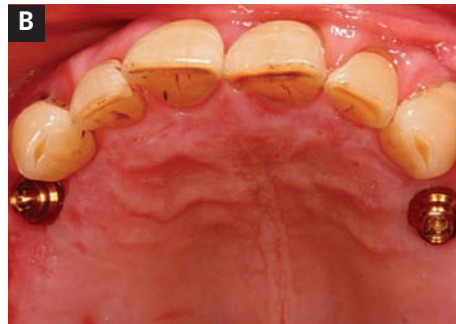

FIGURE 3B Implants and subsequent Locator implant attachments placed bilaterally in the first bicuspid area to provide retention for clasplless implant-retained RPD.

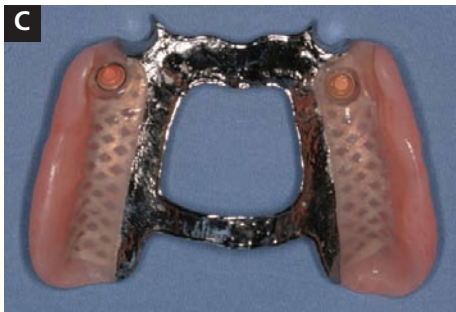

FIGURE 3C Tissue surface of prosthesis, with indirect retention on lingual surface of the cuspids that provided a guide plane and assisted in minimizing rotational movement of the appliance.

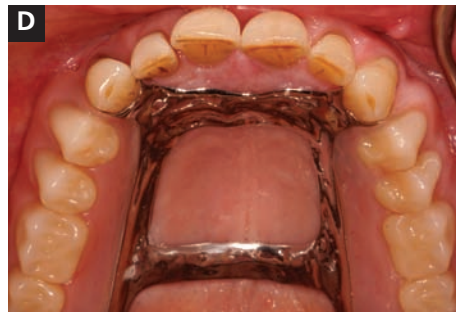

FIGURE 3D Final prosthesis with uncompromised esthetics and retention. RPD created no detrimental forces to the remaining dentition.

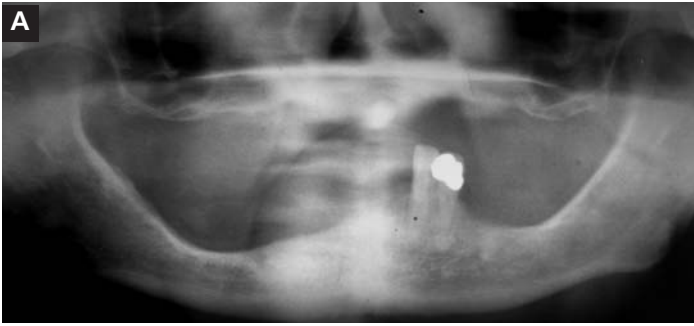


FIGURE 4A Panoamic radiograph of a 70-year-old woman at initial patient presentation.

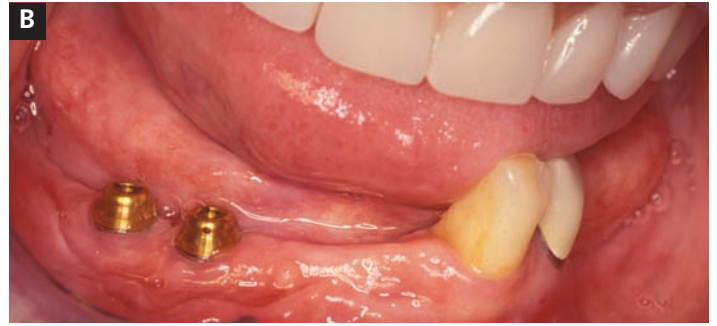

FIGURE 4B The long-span irregularly edentulous ridge of patient who was unable to tolerate her prosthesis before the placement of two implants to provide retention, limitation of rotation, and a level of occlusal support.

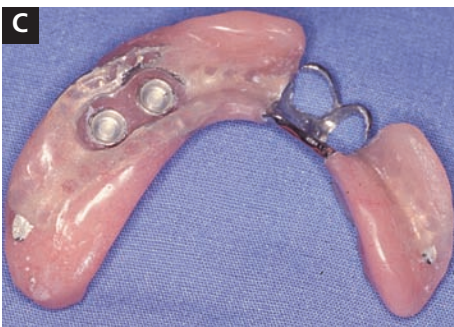

FIGURE 4C Tissue surface of prosthesis with Locator housings and retentive elements cured into base.

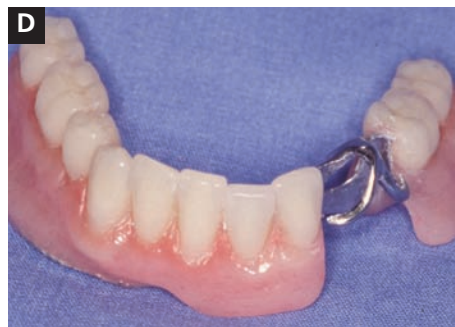

FIGURE 4D Final tooth- and implant-retained appliance.

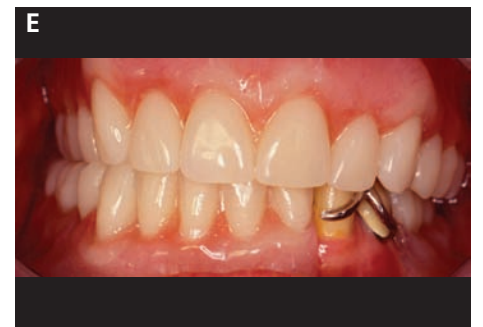

FIGURE 4E Prosthesis in full occlusion opposing an existing maxillary full denture.

provided ideal retention (Figure 4C and Figure 4D), a level of occlusal support (Figure 4E) on the irregular residual ridge with thin overlying mucosa, and the ability to convert to a traditional implant overdenture should the teeth on the left side be lost.

CONCLUSION

Implant-retained RPDs should be presented to patients whenever an RPD is considered or conventional fixed prosthetic options are met with limitations. This treatment modality offers the multitude of benefits of implant-based therapy—biologic, biomechanical, social, and psychological—to more patients.

ACKNOWLEDGEMENT

Thank you to Dr. Harriet McGraw of Petoskey, Michigan, for her assistance in the preparation for this article.

REFERENCES

1. Awad MA, Locker D, Korner-Bitensky N, et al. Measuring the effect of intra-oral implant rehabilitation on health-related quality of life in a randomized controlled clinical trial. *J Dent Res*. 2000;79(9):1659-1663.
2. Feine JS, Carlsson GE, eds. *Implant Overdentures: The Standard of Care for Edentulous Patients*. Chicago, IL: Quintessence Publishing Co; 2003.
3. Vogel RC. Implant overdentures: a new standard of care for edentulous patients—current concepts and techniques. *Functional Esthetics and Restorative Dentistry*. 2007;1(2):30-36.
4. Brudvik JS. *Advanced Removable Partial Dentures*. Chicago, IL: Quintessence Publishing Co; 1999:153-159.
5. Mitrani R, Brudvik JS, Phillips KM. Posterior implants for distal extension

- removable prostheses: a retrospective study. *Int J Periodontics Restorative Dent*. 2003;23(4):353-359.
6. Mijiritsky E. Implants in conjunction with removable partial dentures: a literature review. *Implant Dentistry*. 2007;16(2):146-154.
7. Mijiritsky E, Ormianer Z, Klinger A, et al. Use of dental implants to improve unfavorable removable partial denture design. *Compend Contin Educ Dent*. 2005; 26(10):744-750.
8. Budtz-Jorgensen E, Bochet G, Grundman M, et al. Aesthetic considerations for the treatment of partially edentulous patients with removable dentures. *Pract Periodontics Aesthetic Dent*. 2000;12(8):765-774.
9. Chee WWL. Treatment planning: implant-supported partial overdentures. *J Calif Dent Assoc*. 2005;33(4):313-316.
10. deCarvalho WR, Barboza EP, Caúla AL. Implant-retained removable prosthesis with ball attachments in partially edentulous maxilla. *Implant Dent*. 2001; 10(4):280-284.
11. Kordatzis K, Wright PS, Meijer HJ. Posterior mandibular residual ridge resorption in patients with conventional denture and implant overdentures. *Int J Oral Maxillofac Implants*. 2003;18(3):447-452.

ABOUT THE AUTHOR: Robert C. Vogel, DDS, is a fellow of the International Team for Implantology. He lectures internationally on implant dentistry with an emphasis on simplification, confidence, and predictability of implant prosthetics through ideal treatment planning and team interaction. He maintains a private practice focusing on implant prosthetics and reconstructive dentistry in Palm Beach Gardens, Florida. He may be reached at centricrelation@pol.net.